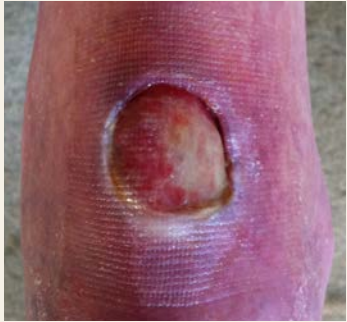

SEVERE WOUND OF EPIDERMOLYSIS BULLOSA (EB) PATIENT TREATED WITH PRINCIPELLE MATRIX AND MELMAX.

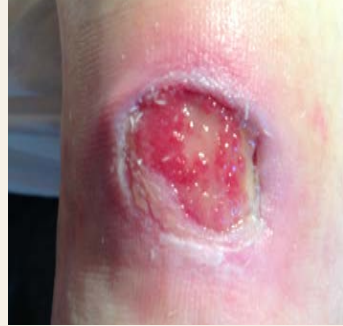t=0



Male (age >80) presents an undermined EB wound on ankle, originating from a blister.

Goal of treatment: promote optimal healing conditions without adhesive dressings, therefore Principelle Matrix non-border was used as a secondary dressing.

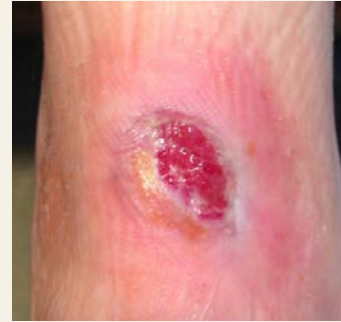
t=15 days



Wound was treated with MelMax honey-based wound dressing to fight infection and Principelle Matrix used for moisture management. Dressing change: every 4-5 days.

Product used:
MelMax (MM081010)
Sterile honey impregnated wound dressing.

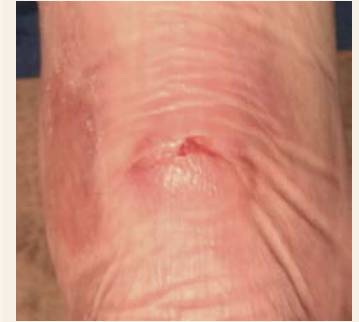t=75 days



Wound healing progress was irregular but increasing. In dry conditions, wound was supported by Principelle IF honey ointment.

Product used:
Principelle Matrix (PPM1010)
Sterile impregnated wound dressing

t=6 months



Whilst position of the wound is delicate, patient is now mobile as if there is no wound at all. Principelle Matrix is used as a *second skin* dressing if wound condition tends to decline.

