

Principelle Case Study Yemen

Philosophy Principelle





- Translating clinical experience and novel ideas into meaningful treatment modalities
- Create Quality and Value to enhance Cost-efficiency



The Principelle Wound Classification Model



Treatment objectives:

-  **Black wounds** Removal of black necrosis
-  **Yellow wounds** Removal of yellow fibrin layer/pus
-  **Red wounds** Acceleration/protection red granulation tissue
-  **Pink wounds** Acceleration/protection pink re-epitheliazation
To achieve complete healing/hydration healed skin with hydrating skin cream

Patient Case Study Yemen

Surgical wound – case 1.

Start treatment
02/11/2016

Patient history:

Age: 13 years

Other: Leukemia

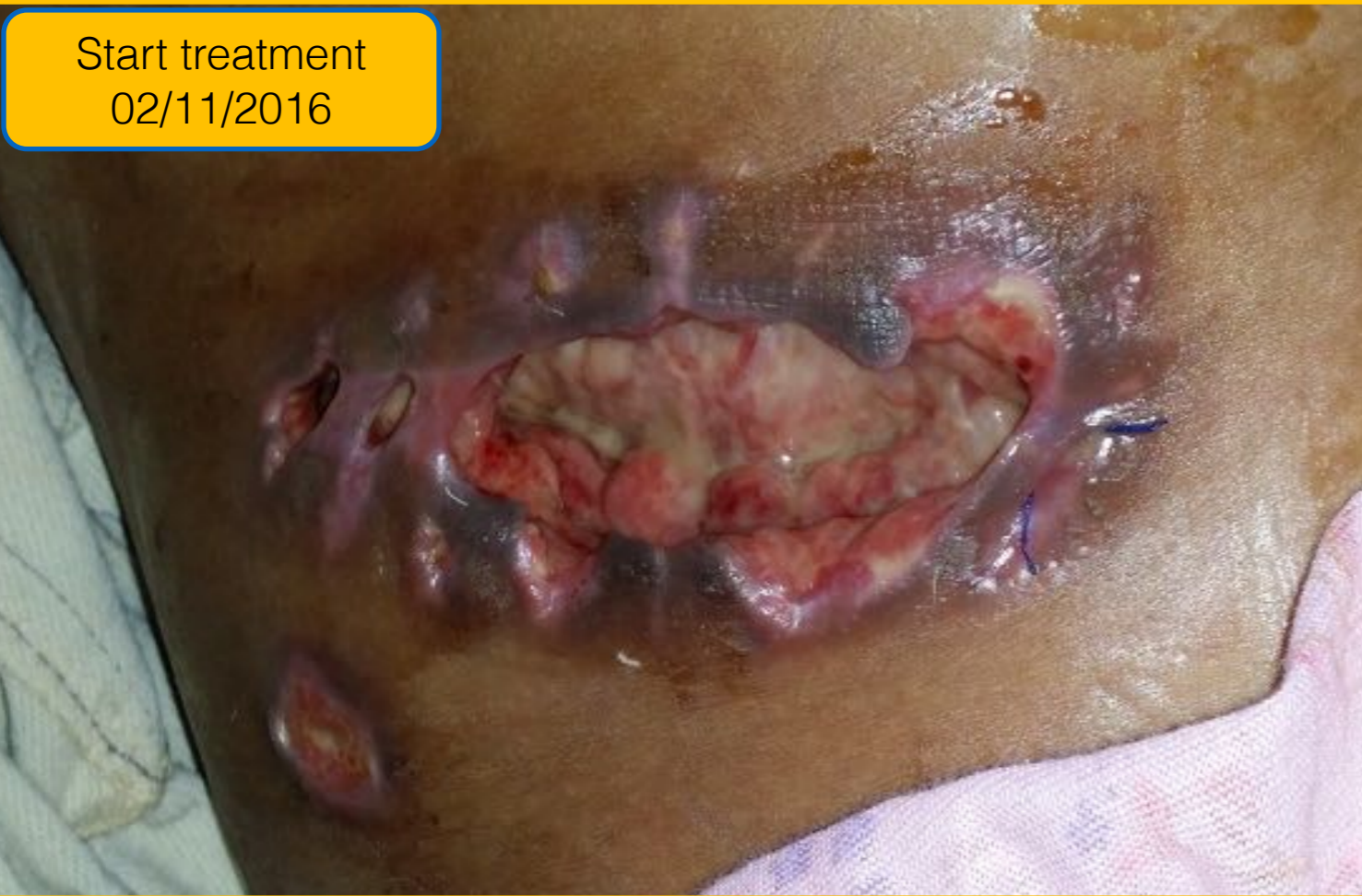Wound:

- Post surgical wound after appendectomy
- Location: Abdominal
- Duration: 3 Weeks
- Mode of exudation:

Patient Case Study Yemen

Surgical wound – case 1.

Start treatment
02/11/2016



Treatment objectives yellow phase:

- Debridement of yellow fibrin layer/pus
- Acceleration granulation tissue
- Reduction of wound size

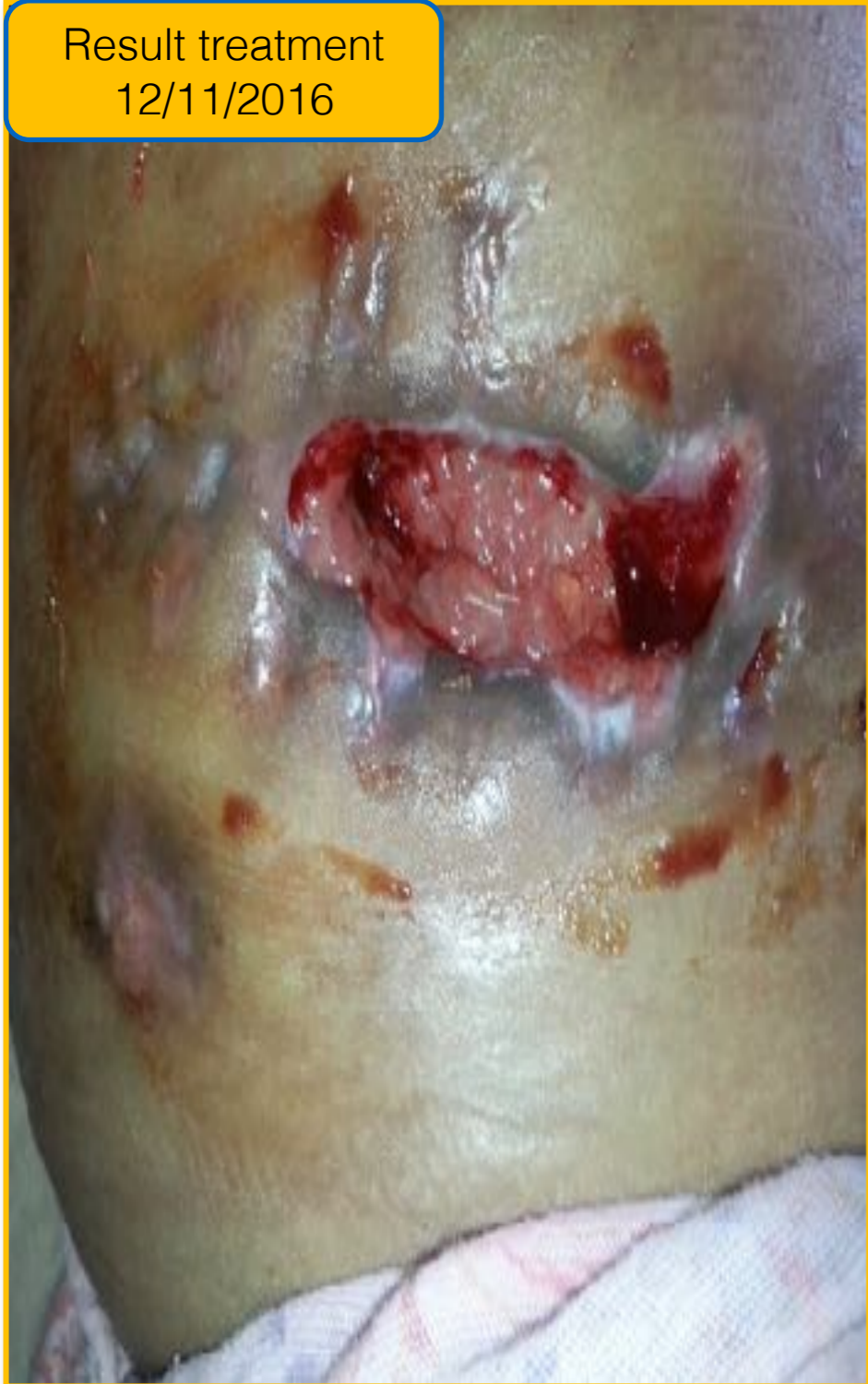Selected treatment:

- Principelle IF ointment
- Secondary dressing:
Principelle Matrix

Patient Case Study Yemen

Surgical wound – case 1.

Result treatment
12/11/2016



Treatment results after 10days:

- Debridement of yellow fibrin layer/pus-achieved
- Acceleration granulation tissue
- Reduction of wound size

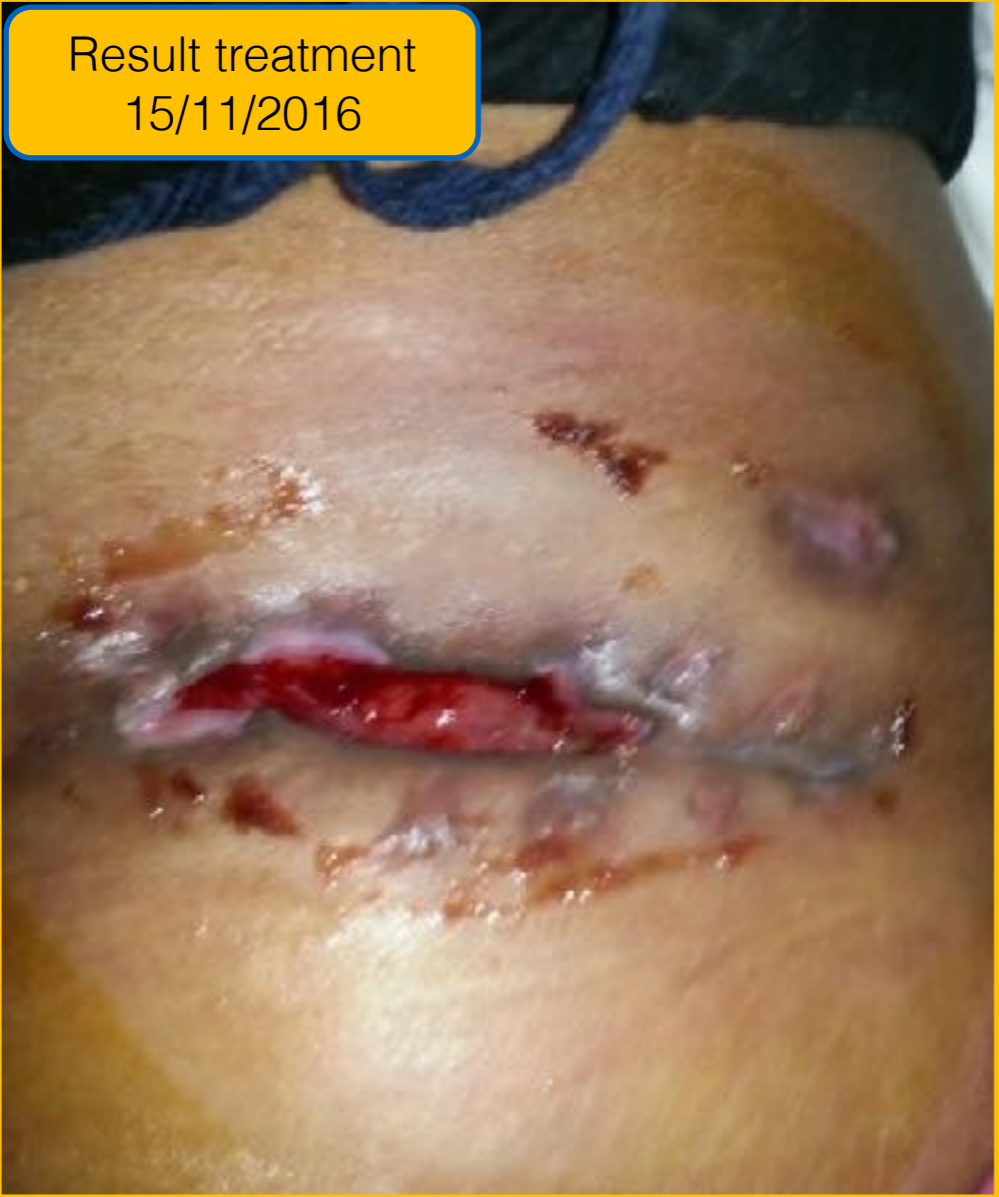Selected treatment:

- Principelle IF ointment
- Secondary dressing:
Principelle Matrix

Patient Case Study Yemen

Surgical wound – case 1.

Result treatment
15/11/2016



Treatment results after 13 days:

- Debridement ongoing
- Acceleration granulation tissue
- Significant reduction of wound size - achieved

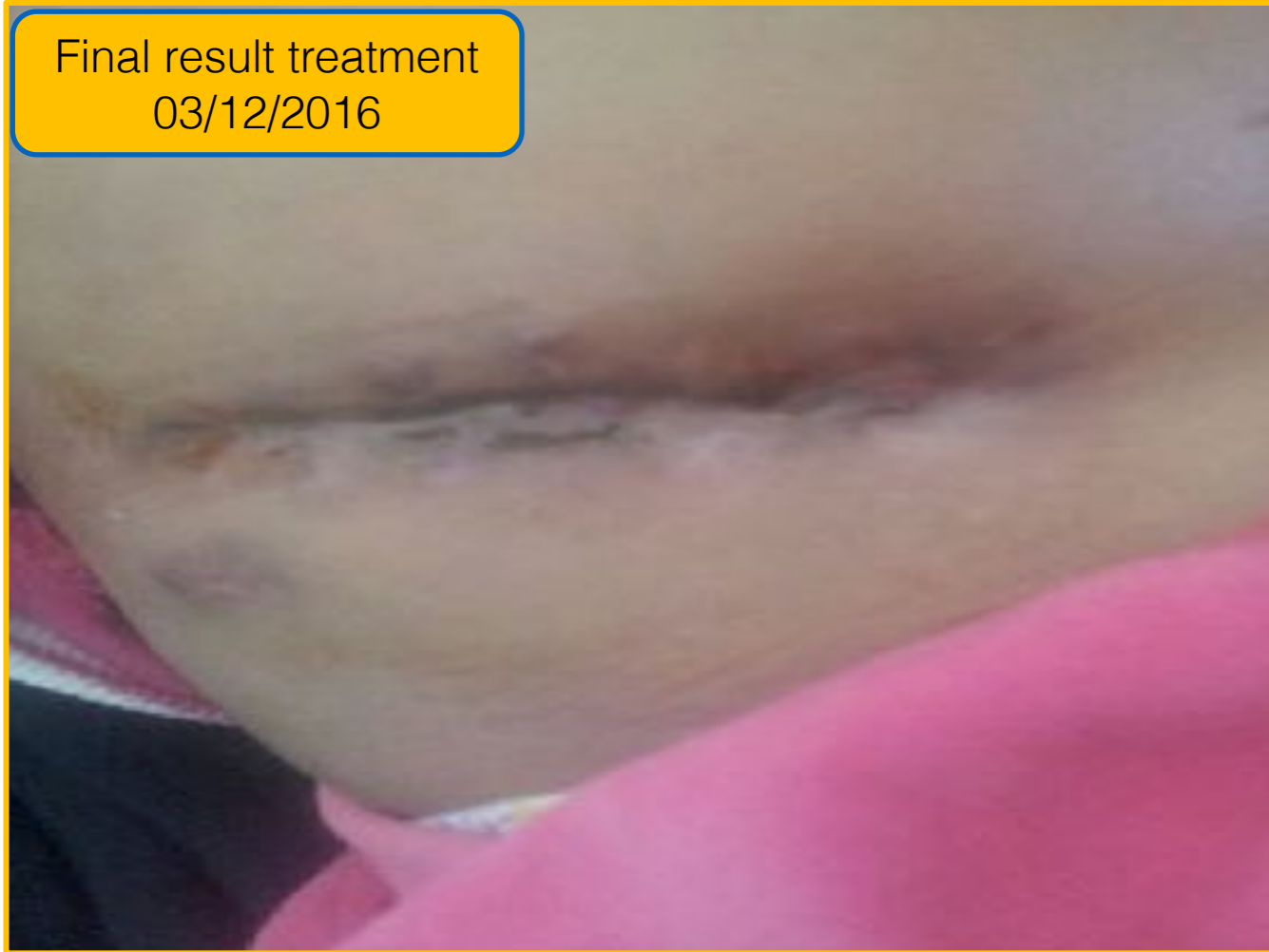Selected treatment:

- Principelle IF ointment
- Secondary dressing:
Principelle Matrix

Result treatment
03/12/2016

Patient Case Study Yemen Surgical wound – case 1.

Final result treatment
03/12/2016



Final results after 4 weeks:

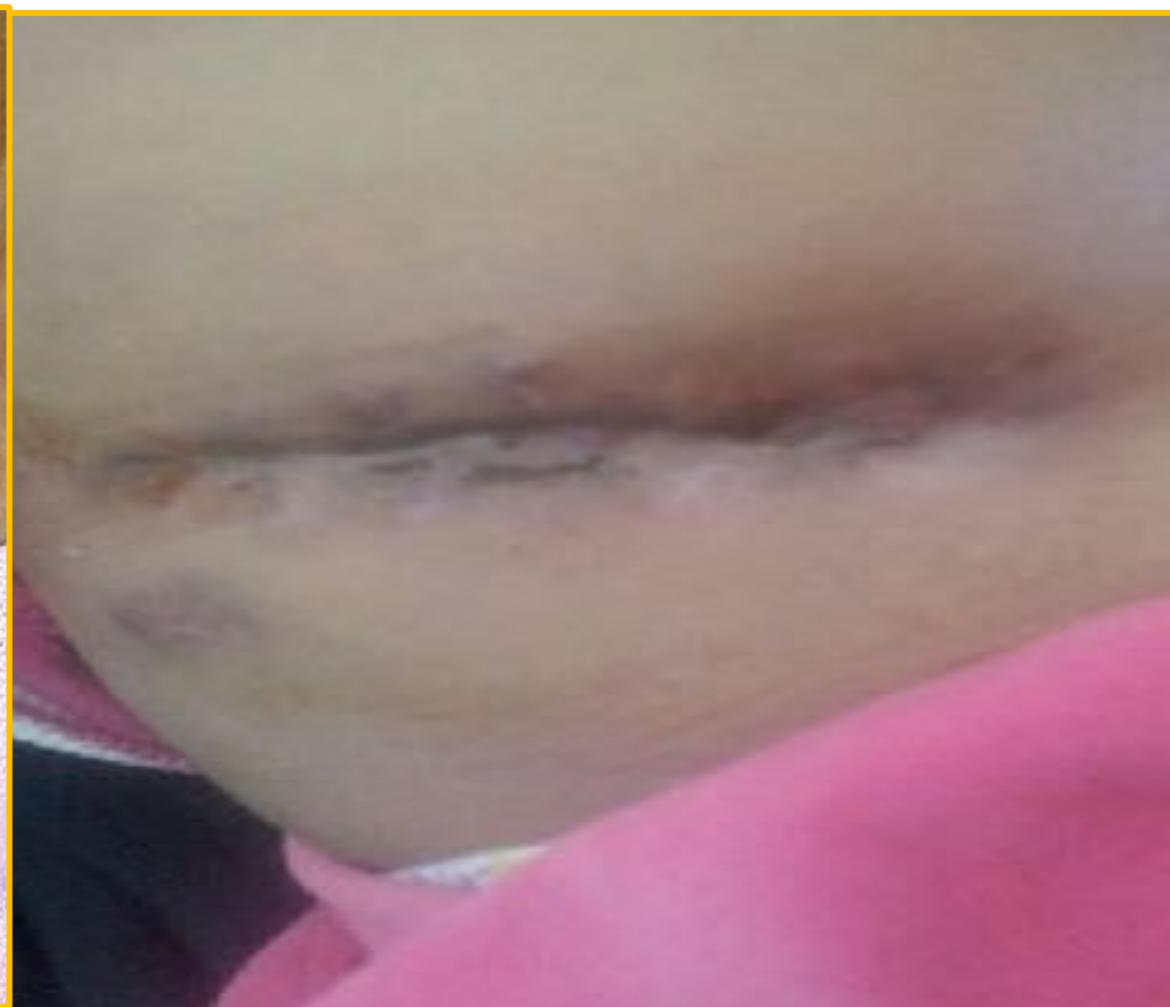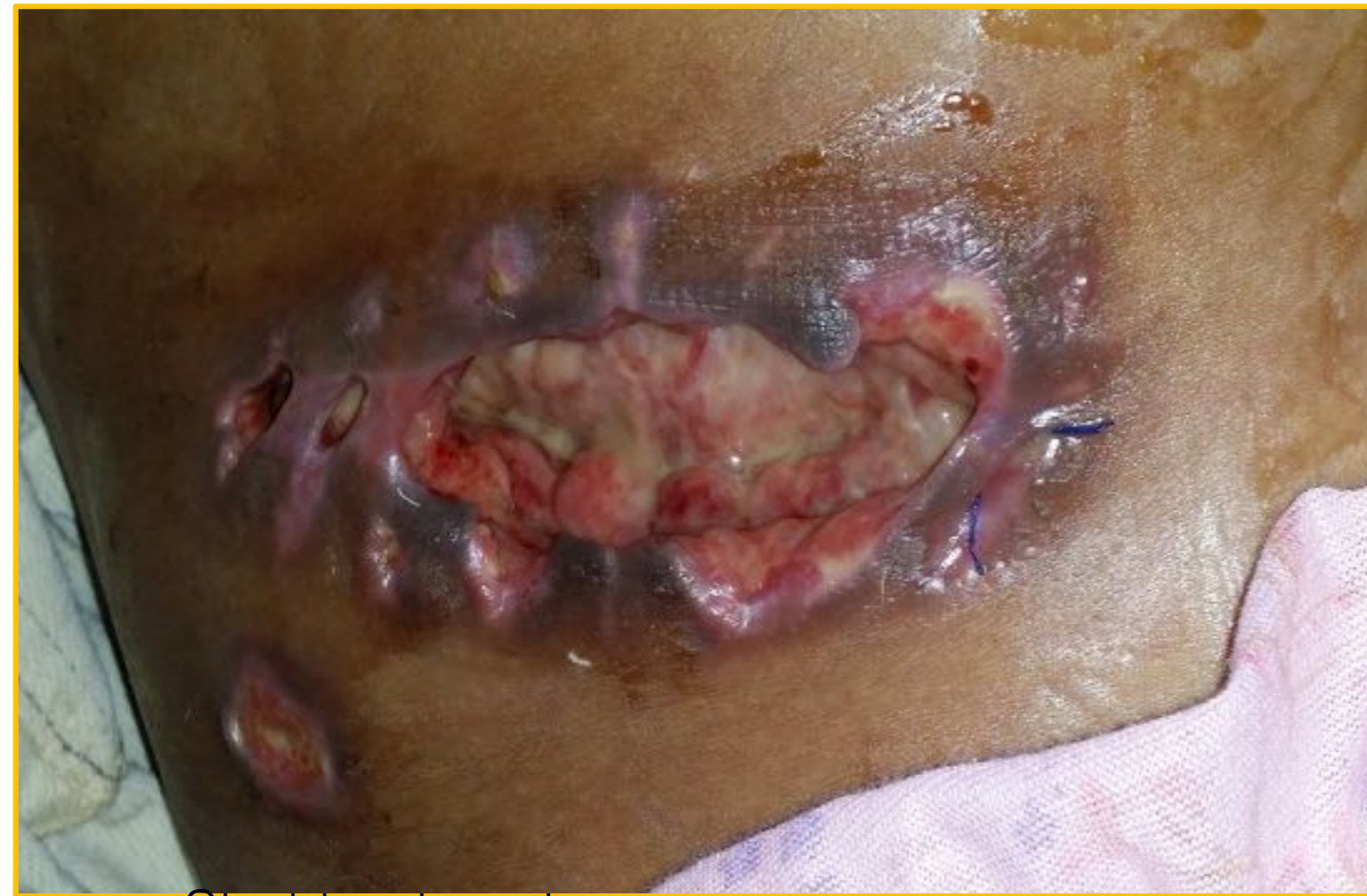- Complete healing achieved

Selected treatment:

- Principelle IF ointment
- Secondary dressing:
Principelle Matrix

Patient Case Study Yemen

Surgical wound – case 1.



Start treatment
02/11/2016
Principelle IF ointment
Principelle Matrix
dressing

Complete healing
03/12/2016
After 4 weeks